

REBASING OF DEFINITIVE OBTURATOR - A CLINICAL CASE REPORT

Dr Sneha Das*¹ and Dr Karunakar Shetty²

*¹Post-Graduate in Prosthodontics, Bangalore Institute Of Dental Sciences And Research Centre, Bangalore

²Professor And Head, Department Of Prosthodontics, Bangalore Institute Of Dental Sciences And Research Centre, Bangalore

Corresponding author: Dr Sneha Das, Post-Graduate in Prosthodontics, Bangalore Institute Of Dental Sciences And Research Centre, Bangalore

Abstract

Rehabilitating patients with maxillofacial defects is one of the most difficult therapies of the stomatognathic system. A comfortable, cosmetically acceptable prosthesis that restores the impaired physiologic activities of speech, deglutition, and mastication is a basic objective of prosthodontic care. Many a time, heavy weight of the obturators is often a dislocating factor. Hollowing the prosthesis to reduce its weight is the well established fact. This article describes the method of rebasing a hollow bulb obturator to make the obturator more retentive, lighter and comfortable to the patient.

Keywords:

Maxillectomy, hollow bulb obturator, rebasing, prosthetic rehabilitation.

INTRODUCTION

Maxillofacial defects may be a result of congenital malformations, trauma or surgical resection of tumors. The primary objective of rehabilitating these defects is to eliminate the disease and to improve the quality of life. ^{1,2,3} Increased weight of the obturator prosthesis is usually a major concern to the prosthodontist. The obturator should be light in weight to provide favorable retention, stability, support, patient comfort and cleanliness. ⁴

This article describes the clinical report of a patient wearing a definitive obturator prostheses which was heavy and uncomfortable due to inadequate seal of the prostheses with the surrounding tissue.

CLINICAL REPORT

A 69 year old female patient reported to the Department of Prosthodontics, Crown and Bridge at Bangalore Institute of Dental Sciences and Hospital, Bangalore with a chief complaint of inability to talk and chew. Past dental history revealed cystic growth in the left maxilla invading the left maxillary sinus which was resected in 2014 by subtotal maxillectomy.

Clinical examination revealed well healed resected maxilla (fig 1.) Patient also reported wearing an obturator since 4 months but discontinued its use as it was loose and uncomfortable. Support for the obturator was taken by wrought wire clasps engaging 11, triangular clasp in between 14 and 15 and a circumferential clasp engaging 16. The obturator appeared to be good but was not retentive (fig 2.) A noticeable gap was seen in between the obturator and the left buccal mucosa. Patient's mouth opening, temporomandibular joint and saliva were examined and found to be normal.

General examination revealed no relevant medical history.

The patient was explained about the treatment plan options i.e either a new definitive obturator or rebasing the previous obturator.

Since the patient needed the obturator in a very short period of time, rebasing of the existing obturator was the choice of treatment.

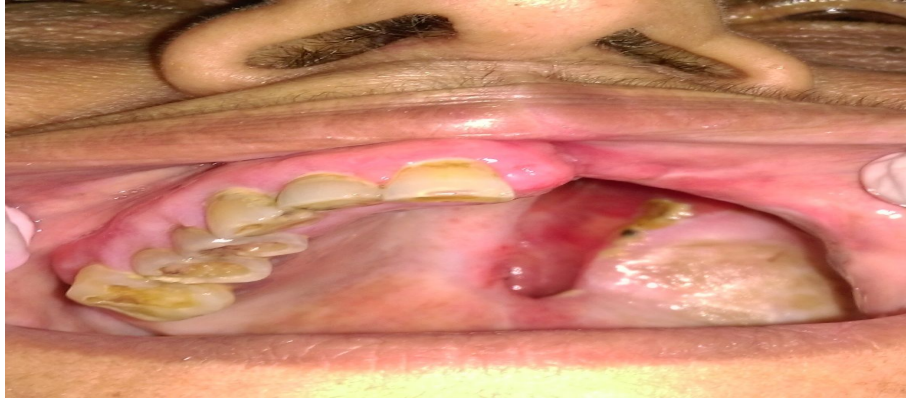

Fig 1. Well healed maxillary defect

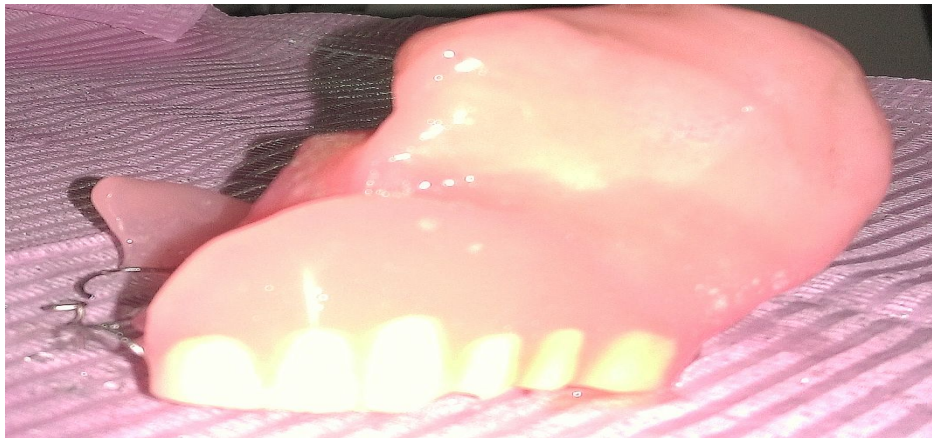

Fig 2. Existing obturator

TREATMENT PROCEDURES

- 1) The existing obturator of the patient was washed and sterilized and used as a custom tray for making impression of the maxillary defect.
- 2) The borders of the obturator were evaluated and checked for extensions.
- 3) Tray adhesive (VPS, 3M ESPE, Seefeld, Germany) was applied and border molding was done in single step using putty (Aquasil soft putty, Dentsply Caulk, Milford USA)
- 4) Poly vinyl siloxane material (Aquasil Ultra LV Dentsply Caulk, Milford , USA) was placed in the defect area of the obturator and an impression was made (fig 3). The impression was washed and poured with Type III dental stone.
- 5) The portion of the obturator to be rebased was reduced by means of a rotary cutting instrument. leaving only the artificial teeth and the portion of the obturator engaging the clasps.

- 6) The obturator was placed in the cast and a wax pattern was made covering the defect area. (fig 4.)
- 7) It was invested in a dental flask and dewaxed (fig 5)
- 8) The hollow bulb obturator was made using lost salt technique. A thin layer of heat cure acrylic resin (Trevalon Hi, Dentsply India, Gurgaon, India) was placed in the defect area of the mold and covered with salt filling the concavity completely. (fig 6)
- 9) A layer of heat cure acrylic resin was placed on top of it in dough stage and packed and cured at 74°C for 8 hours..
- 10) After retrieval of the obturator, the interior surface was checked carefully to locate any nodules or irregularities.
- 11) 3 holes were made in the roof of the hollow bulb of the obturator and the salt was removed using hot water and syringe until the bulb was completely empty.
- 12) The holes were closed using self cure acrylic resin (Trevalon Hi, Dentsply India, Gurgaon, India).
- 13) Finally the obturator was finished and polished.
- 14) The obturator was then placed in the patient's mouth (fig 7) and was checked for occlusal discrepancies using articulating paper and slight adjustment was done with the clasp engaging the right central incisor.

The patient was satisfied with the new definitive obturator prosthesis as it was light in weight, retentive, comfortable and her speech was much better.

The patient was recalled after 7 days for follow up and was evaluated for speech, retention and esthetics. Following this, she was followed up every three months for the next 1 year.

Discussion:

Maxillary obturator prosthesis is a more frequent treatment modality than surgical reconstruction due to ease of fabrication and maintenance.⁴ Effective obturation of maxillary defects produces sufficient separation of the oral and nasal cavity to improve the quality and intelligibility of speech.¹

In the present case report, rebasing of the existing definitive obturator was chosen as the treatment option because it required less time rather than fabricating a new prosthesis as the patient had time constraints. Steps like arrangement of teeth, try in, fabrication of clasps were eliminated in this procedure.

Several techniques and materials have been described previously to fabricate a lightweight, hollow obturator.⁴ To grind out the interior of the bulb after processing while maintaining the thickness of the walls was the basic classic technique used for hollowing an obturator.^{4,5} Materials such as sugar^{4,5,6} and ice^{4,5} were used to create the hollow space inside the processed resin. Two-step processing technique, using preformed plastic shapes or plaster matrix were tried by some authors.^{4,9,11} The acrylic resin shim and a polyurethane foam were incorporated into the defect area to create hollow space. In this case, salt was used to make the hollow bulb as salt is easy to remove using hot water because of its fine granules.

Recording of the borders by single step border molding technique using putty was done because of certain advantages like simplicity, ease of manipulation, decreased discomfort to the patient, short chair side time and accurate reproduction of undercut areas.¹¹

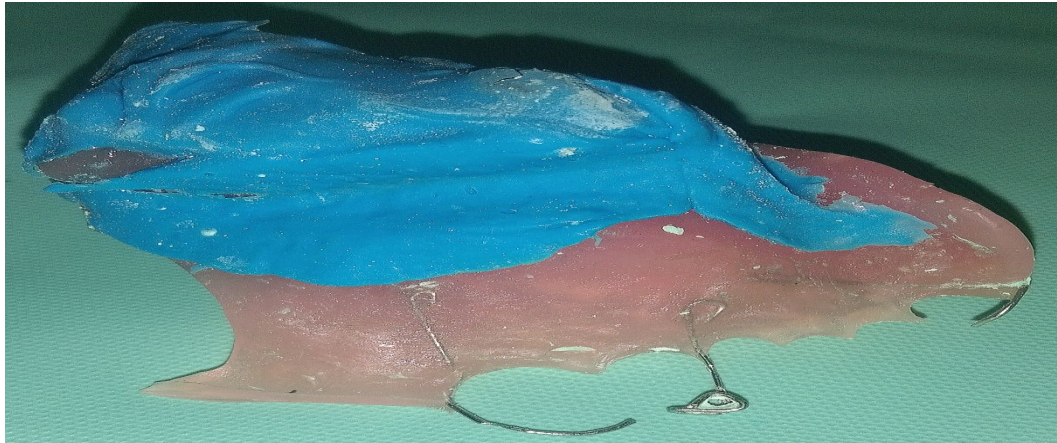


Fig. 3. Impression of the defect area



Fig. 4. Wax pattern of the defect area

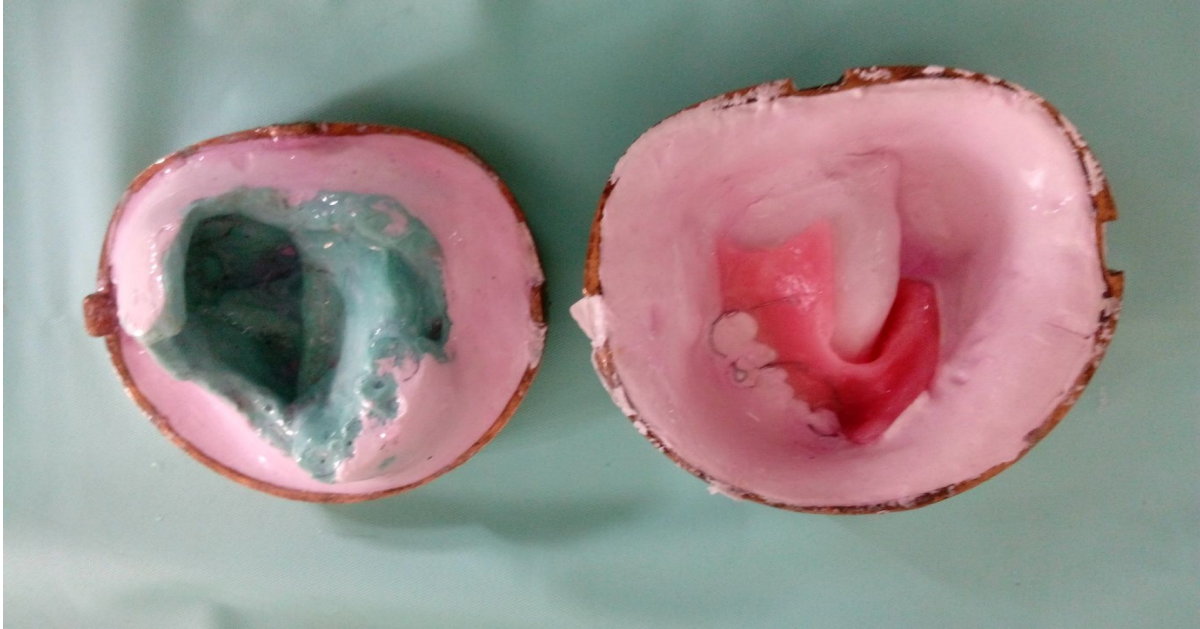

Fig 5. Dewaxing of the wax pattern



Fig 6. Salt in the defect area to create hollow bulb

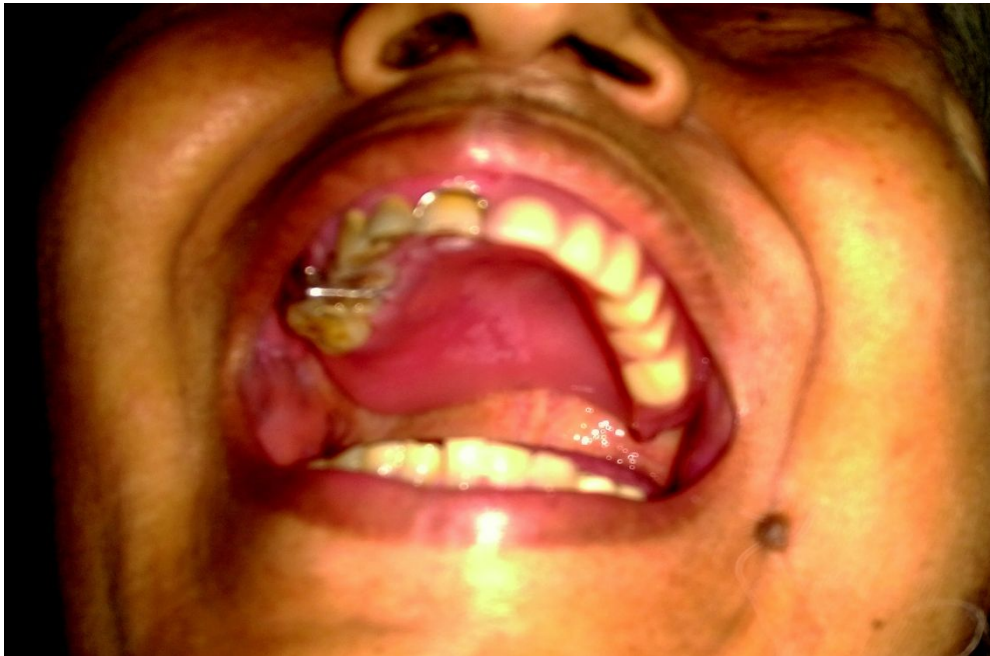

Fig 7. Definitive obturator in patient's mouth



Extraoral view of patient wearing obturator

CONCLUSION

Though it is difficult to improve the quality of life for hemimaxillectomy patients compared with patients with conventional prostheses, it can nevertheless be achieved with skill and experience of specialists. The problem experienced by hemimaxillectomy patients are reduced if a team approach is adopted and specialists are careful to apply skill and experience at all stages and keep the patient under regular review. With regard to prosthesis, sometimes treatment options are governed by patients demands not only in the oral cavity but out of it too. The present case report thus presents a effective treatment option given the constraints with regard to patients demands and time.

REFERENCES

1. Kiran Kumar Thota, Suchita Tella, Anulekha Avinash CK, Rajyalakshmi Ravuri. *A Prosthodontic Rehabilitation of a Partial Maxillectomy Patient with Hollow Bulb Obturator. IJDA, 2(4), October-December, 2010; 383-386*
2. Lethaus B, Lie N, de Beer F, Kessler P, de Baat C, Verdonck HW. *Surgical and prosthetic reconsiderations in patients with maxillectomy. J Oral Rehabil. 2010 Feb;37(2):138-42.*
3. Bajaj Pankaj, Shweta, Kumar Ajit, Sikka Rohan, *Maxillary obturator prosthesis rehabilitation: Case series of three patients. Bfudj, Volume 5, Number 3, Oct. 2014; 1-6*
4. Pravinkumar G. Patil, *Modified technique to fabricate a hollow light-weight facial prosthesis for lateral midfacial defect: a clinical report . J Adv Prosthodont 2010;2:65-70*
5. Pravinkumar Gajanan Patil, Smita Pravinkumar Patil. *A hollow definitive obturator fabrication technique for management of partial maxillectomy. J Adv Prosthodont 2012;4:248-53*
6. Brown KE. *Clinical considerations improving obturator treatment. J Prosthet Dent 1970;24:461-6.*
7. McAndrew KS, Rothenberger S, Minsley GE. 1997 Judson C. Hickey Scientific Writing Awards. *An innovative investment method for the fabrication of a closed hollow obturator prosthesis. J Prosthet Dent 1998;80:129-32.*
8. Matalon V, LaFuente H. *A simplified method for making a hollow obturator. J Prosthet Dent 1976;36:580-2.*
9. Beder OE, Todo J. *Rapid technique for constructing a hollow- bulb provisional obturator. J Prosthet Dent 1978;39:237-9.*
10. Nidiffer TJ, Shipmon TH. *The hollow bulb obturator for acquired palatal openings. J Prosthet Dent 1957;7:126-34*
11. Rameshbabu Yarapatineni¹, Abhishek Vilekar², J Phani Kumar³, G Ajay Kumar⁴, Prasad Aravind⁵, P Anil Kumar⁶ *Comparative evaluation of border molding, using two different techniques in maxillary edentulous arches - An in vivo study. Journal of International Oral Health. Nov-Dec 2013; 5(6):82-7*

12. Mayank Singh, Akshay Bhushan, Narendra Kumar, Sharad Chand. Obturator prosthesis for hemimaxillectomy patients. National Journal of Maxillofacial Surgery | Vol 4 | Issue 1 | Jan-Jun 2013 |, 117-120
13. Süha Türkaslan, Timuçin Baykul, M Asım Aydın³ and M Mustafa Özarlan. Influence of immediate and permanent obturators on facial contours: a case series. Cases Journal 2009, 2:6;1-5
14. Bijay Kunwar Singh. A simplified technique for constructing one piece hollow bulb obturator after partial maxillectomy. IJOPRD, July- Sept. 2011;1(2);118-122
15. Zarb GA. The maxillary resection and its prosthetic replacement. J Prosthet Dent 1967;18(3):268-81.